

Vanderlaan, Jon



ATTORNEY GENERAL OF TEXAS
GREG ABBOTT

RECEIVED

MAR 22 2013

CIVIL DIVISION
DISTRICT ATTORNEY'S OFFICE

March 20, 2013

Ms. Ashley D. Fourt
Assistant District Attorney
Tarrant County
401 West Belknap, Ninth Floor
Fort Worth, Texas 76196-0201

OR2013-04598

Dear Ms. Fourt:

You ask whether certain information is subject to required public disclosure under the Public Information Act (the "Act"), chapter 552 of the Government Code. Your request was assigned ID# 486699.

The Tarrant County Medical Examiner's Office (the "medical examiner's office") received three requests from the same requestor for information related to a specified autopsy report. You claim the submitted information is excepted from disclosure under section 552.108 of the Government Code. We have considered the claimed exception and reviewed the submitted information.

Section 552.108(a)(1) of the Government Code excepts from disclosure "[i]nformation held by a law enforcement agency or prosecutor that deals with the detection, investigation, or prosecution of crime . . . if . . . release of the information would interfere with the detection, investigation, or prosecution of crime[.]" Gov't Code § 552.108(a)(1). A governmental body must reasonably explain how release of the information at issue would interfere with the detection, investigation, or prosecution of crime. *See id.* § 552.301(e)(1)(A) (governmental body must provide comments explaining why exceptions raised should apply to information requested); *see also Ex parte Pruitt*, 551 S.W.2d 706 (Tex. 1977). Section 552.108 applies to information held by a "law enforcement agency." However, section 552.108 may be invoked by the proper custodian of information relating to a pending investigation or prosecution of criminal conduct. *See Open Records Decision No. 474 at 4-5 (1987)*. Thus, where a non-law enforcement agency has custody of information that would

otherwise qualify for exception under section 552.108 as information relating to the pending case of a law enforcement agency, the custodian of the records may withhold the information if it provides this office with a demonstration that the information relates to the pending case and a representation from the law enforcement agency that it wishes to have the information withheld.

You state, and have provided an affidavit from the Ector County Sheriff's Department (the "department") confirming, that the department objects to disclosure of the submitted information because its release would interfere with an ongoing criminal investigation. Based on this representation, we conclude the medical examiner's office may withhold the submitted information under section 552.108(a)(1) of the Government Code on behalf of the department. *See Houston Chronicle Publ'g Co. v. City of Houston*, 531 S.W.2d 177 (Tex. Civ. App.—Houston [14th Dist.] 1975) (court delineates law enforcement interests that are present in active cases), *writ ref'd n.r.e. per curiam*, 536 S.W.2d 559 (Tex. 1976).

This letter ruling is limited to the particular information at issue in this request and limited to the facts as presented to us; therefore, this ruling must not be relied upon as a previous determination regarding any other information or any other circumstances.

This ruling triggers important deadlines regarding the rights and responsibilities of the governmental body and of the requestor. For more information concerning those rights and responsibilities, please visit our website at http://www.oag.state.tx.us/open/index_orl.php, or call the Office of the Attorney General's Open Government Hotline, toll free, at (877) 673-6839. Questions concerning the allowable charges for providing public information under the Act must be directed to the Cost Rules Administrator of the Office of the Attorney General, toll free, at (888) 672-6787.

Sincerely,



Cindy Nettles
Assistant Attorney General
Open Records Division

CN/dls

Ref: ID# 486699

Enc. Submitted documents

c: Requestor
(w/o enclosures)

1301059



Ector County Medical Examiner
Nathan C. Galloway, M.D., Medical Examiner
Facsimile (432) 617-3299

200A W. 3RD
Odessa, Texas 79761
(432) 617-3296

Date: January 22, 2013

This authorizes the Office of Chief Medical Examiner of Tarrant County, Texas, to release the body and all property of Max Allan Shatto and whose date of birth is 1-9-2010 to Texas Overland Transport


The "Chain of Custody for Transport of Body" sheet will need to be signed by the Person releasing custody and the person accepting custody.

A handwritten signature in cursive script that reads "Nathan C. Galloway". The signature is written over a horizontal line.

Nathan C. Galloway, M.D.
Medical Examiner
Ector County, Texas

NCG: WF

DEATH INVESTIGATION REPORT



Medical Legal Number 13-01-075-A

Investigator Sondra Woolf

Decedent's Name (First, Middle, Last) <u>Max Allan Shatto</u>							
Age	<u>3</u>	Race	<u>W</u>	Sex	<u>M</u>	DOB	<u>1-9-2010</u>
SS#	<u>N/A</u>		Telephone #	<u>432-557-9258</u>			
Home Address		<u>16097</u>	<u>Waldrop</u>	<u>Gardendale</u>	<u>Ector</u>	<u>Texas</u>	<u>79758</u>
		Street #	Street Name	City	County	State	Zip
Marital Status:	<input checked="" type="checkbox"/> Single	<input type="checkbox"/> Married	<input type="checkbox"/> Divorced	<input type="checkbox"/> Separated	<input type="checkbox"/> Widow(er)	<input type="checkbox"/> Common Law	<input type="checkbox"/> Unknown
Children:	<u>N/A</u>						
Decedent Occupation & Employment Status:	Occupation or Job Title		<u>N/A</u>				
	<input type="checkbox"/> Retired	<input type="checkbox"/> Disabled	<input type="checkbox"/> Unknown	<input type="checkbox"/> Employed	<input type="checkbox"/> Unemployed	<input type="checkbox"/> Self Employed	

DESCRIPTION OF CIRCUMSTANCES (includes how the incident is thought to have occurred, decedent's activity at the time of the incident, the type of place, and the sequence of events)

See Attached Narrative.

Clothing:	<input type="checkbox"/> L.E.	<input type="checkbox"/> Family	<input type="checkbox"/> Funeral Home	<input checked="" type="checkbox"/> M.E.	<input type="checkbox"/> Hospital Security	<input type="checkbox"/> Contaminated/Disposed
Valuables:	<input type="checkbox"/> L.E.	<input type="checkbox"/> Family	<input type="checkbox"/> Funeral Home	<input type="checkbox"/> M.E.	<input type="checkbox"/> Hospital Security	<input checked="" type="checkbox"/> No Valuables
Photos taken by ME Investigator:	<input checked="" type="checkbox"/> Yes	<input type="checkbox"/> No	Photos taken by dispatched agency:	<input checked="" type="checkbox"/> Yes	<input type="checkbox"/> No	
Death Place:	<input type="checkbox"/> On Scene	<input checked="" type="checkbox"/> Emergency Room	<input type="checkbox"/> In surgery	<input type="checkbox"/> In Patient	<u>MCH ED #14</u>	
Concerning the onset of fatal events & place:	<input type="checkbox"/> Witness Present	<input type="checkbox"/> No Witness Known	<input checked="" type="checkbox"/> At own residence	<input type="checkbox"/> Not at own residence		
	<input type="checkbox"/> Indoors	<input checked="" type="checkbox"/> Out of Doors	<input type="checkbox"/> In vehicle	<input type="checkbox"/> On Job		
	Describe Type of Place: <u>In back yard of own residence</u>					
Preliminary Class:	<input type="checkbox"/> Homicide	<input type="checkbox"/> Suicide	<input type="checkbox"/> Accident	<input type="checkbox"/> Natural	<input checked="" type="checkbox"/> Undetermined	
Agency Dispatched:	<u>ECSO</u>	Agency Offense No.:	<u>161794</u>	Officers on Scene:	<u>Det. Jones, ECSO Patrol, ECSO CSU</u>	
Agency Lead Investigator:		Agency Dispatch Time:	<u>1649</u>	Agency Scene Arrival Time:	<u>1719</u>	
EMS Units Dispatched:	<u>R8, E8</u>	EMS Dispatch Time:	<u>1647</u>	EMS Scene Arrival Time:	<u>1704</u>	
ACTION	DATE	TIME	LOCATION / ADDRESS	BY WHOM (PERSON OR AGENCY)		
ME Notified	<u>1-21-13</u>	<u>1747</u>	<u>By Phone</u>	<u>MCH ED Staff</u>		
Found dead						
Found down	<u>1-21-13</u>	<u>~1646</u>	<u>16097 Waldrop</u>	<u>Laura Shatto - Mother</u>		
Known Alive	<u>1-21-13</u>	<u>~1600</u>	<u>16097 Waldrop</u>	<u>Laura Shatto - Mother</u>		
Fatal Injury						
At Hospital	<u>1-21-13</u>	<u>1731</u>	<u>MCH ED</u>	<u>OFD</u>		
Scene Visit	<u>1-21-13</u>	<u>1805</u>	<u>MCH ED #14</u>	<u>Inv. Sondra Woolf</u>		
Pronounced	<u>1-21-13</u>	<u>1743</u>	<u>MCH ED #14</u>	<u>Dr. Diaz</u>		
Placed in Morgue	<u>1-21-13</u>	<u>2005</u>	<u>MCH Morgue</u>	<u>Inv. Sondra Woolf</u>		
Funeral Home:	<u>Nalley, Pickle, and Welch FH - Midland, TX</u>		Chosen By:	<u>Family</u>		

Position of Body
 Sitting On Side On Stomach Laying, Position unspecified Hanging
 Other, Describe: On back on hospital bed

Body Decomposition
 Yes No **Livor Present:** Yes No Location: On back Set

Body Temperature
 Cold Cool Warm **Rigor:** None Early Moderate Set

DVT Measurements
 Measurement required Yes No Left Calf: _____ Right Calf: _____ Total DVT Score: _____

Clothing/ Property On body
 White t-shirt and blue and black thermal long sleeved shirt (cut by medical), soiled diaper off of body, blue jean overalls and pair of white socks and black and red athletic shoes (in bag)

MEDICAL THERAPY IN PLACE

ET Yes No **NG / O/G** Yes No **CENTRAL LINE** Yes No

FOLEY CATH Yes No **C COLLAR** Yes No **FEMORAL LINE** Yes No

BP CUFF Yes No **COMBO PADS** Yes No **TEMP INDICATOR** Yes No

I/O Yes No (Specify): _____

IV Yes No (Specify): _____

EKG STRIPS Yes No (Specify): _____

OTHER Yes No (Specify): _____

NOK Notified Yes No Date: 1-21-13 Time: _____ By Whom: ECSO

NOK Name: Alan and Laura Shatto **Relationship:** Parents

NOK Address: 16097 Waldrop; Gardendale, TX 79758 **Telephone No.:** 432-557-9258

NOK Name: _____ **Relationship:** _____

NOK Address: _____ **Telephone No.:** _____

Dr. Signing DC: Dr. Galloway **Primary Physician:** Dr. Bruce Eckel **Telephone No.:** 940-898-1477

Medical History Not Investigated Unknown No Past Problems Past Medical Problems

Medical Information Source Physician Medical Records Health Provider Family Other: _____

Medical Conditions

<input type="checkbox"/> CHF	<input type="checkbox"/> CAD	<input type="checkbox"/> MI	<input type="checkbox"/> ASCAD
<input type="checkbox"/> Atrial Fibrillation	<input type="checkbox"/> By-Pass Surgery	<input type="checkbox"/> MRSA	<input type="checkbox"/> Anemia
<input type="checkbox"/> Hypertension	<input type="checkbox"/> Hypotension	<input type="checkbox"/> Emphysema	<input type="checkbox"/> COPD
<input type="checkbox"/> Resp. Failure	<input checked="" type="checkbox"/> Bronchitis	<input type="checkbox"/> Pneumonia	<input type="checkbox"/> Asthma
<input type="checkbox"/> Stroke / CVA	<input type="checkbox"/> Dementia	<input type="checkbox"/> Alzheimer's	<input type="checkbox"/> Anxiety
<input type="checkbox"/> Diabetes	<input type="checkbox"/> Pregnant (90 days)	<input type="checkbox"/> Obesity	<input type="checkbox"/> Cancer
<input type="checkbox"/> Renal Failure	<input type="checkbox"/> Cirrhosis	<input type="checkbox"/> Hepatitis	<input type="checkbox"/> Seizures
<input type="checkbox"/> Aneurysm	<input type="checkbox"/> Sleep Apnea	<input type="checkbox"/> Hyperlipidemia	<input type="checkbox"/> PE
<input type="checkbox"/> GERD	<input type="checkbox"/> Osteoarthritis	<input type="checkbox"/> Allergies	<input type="checkbox"/> Sepsis
<input type="checkbox"/> HIV/AIDS	<input type="checkbox"/> Smoker	<input type="checkbox"/> Alcohol	<input type="checkbox"/> Drugs
<input type="checkbox"/> Depression	<input type="checkbox"/> Mental Illness	<input type="checkbox"/> Suicidal Ideation(s)	

Suicide Attempt(s): Method(s) attempted _____

Other Constipation, possible inguinal hernia, conduct disorder, colds, prenatal encephalopathy, allergodermatitis

Notes on Medical History:

According to medical records birth mother could have possibly drank alcohol while pregnant
 Psycho-motor and speech delay

Was the Decedent recently involved in an accident? Yes No Date/ Describe Accident/Injury: Multiple bruises explained by family as being due to self injury by the child, also several abrasions and scratches explained as being from the same cause

Recent travel to foreign country? Yes No Place Traveled/ Date: Traveled to USA from Russia on 11-3-2012

Recent Methadone Use? Yes No Last Use Date: _____ Prescribed to decedent Yes No

Medication History Not Investigated Unknown Prescription Meds Over-the-counter Meds None

Medications Collected on scene Yes No **Medication log attached** Yes No

Agonal Medical Treatment None CPR Transfusion IV Fluids Surgery Defibrillation

Autopsy Yes No **Autopsy Location:** Tarrant County **Autopsy Type:** Full Limited External Exam

Family Notified of Autopsy Yes No N/A **Date/ Time Notified:** 1-21-13 / ~1910 hrs

Ector County Medical Examiner's Office

Narrative Report

Date/Time: 1-21-13 / 1747 hrs

ML# 13-01-075-A

Investigator: Sondra Woolf

Decedent: Max Allan Shatto

On the above date and time our office was contacted by MCH ED Staff in reference to a deceased person at the ED in room 14. The decedent was identified to me as **Max Allan Shatto**, w/m, DOB 1-9-2010. According to ED Staff and hospital records he had arrived at the hospital via OFD ambulance at 1731 hrs after being found unresponsive and not breathing at his residence by his mother. The decedent had life saving measures in progress by OFD upon arrival to the ED at MCH and they continued at the ED but were unsuccessful. The decedent was pronounced deceased at 1743 hrs by Dr. R. Diaz. The decedent had arrived in the ED with no family present and was identified as PT, NO ID 1629 in the hospital records.

I arrived at the scene at 1805 hrs and was directed to ED #14. Upon my arrival to the ED I spoke with one of the firefighters that were still present at the ED and he advised that they had been dispatched to the decedent's residence because he had been found unresponsive and not breathing by his mother. The Firefighter advised that they had transported the decedent to the ED and that the decedent's mother had remained at the residence and simply told them as they were leaving the house with the decedent that she would be at the hospital in a minute. I then proceeded into ED #14. I was met by ECSO Inv. Jones and he advised that he was dispatched to the hospital on this case and that he had just arrived. We entered the room together and I observed the decedent lying on the hospital bed covered with a white hospital blanket. I removed the blanket and noted that the decedent was clothed in a white t-shirt and black and blue striped thermal long sleeved shirt that had both been cut by medical. There was a soiled diaper lying on the hospital bed between his legs that had been removed by medical personnel and medical therapy was in place. The decedent appeared to be thin and livor was present on the decedent's back. Rigor was not present and the body was warm to the touch. The decedent had several injuries on his body that included: a dark purple circular bruise on the left side of his head directly in front of the left ear, two purple small bruises in the left temple area, a light pink small bruise on the left cheekbone, purple discoloration under the left eye, a hemorrhage on the inside corner of the left eye, a scabbed abrasion on the left side of the face to the left of the outer corner of the mouth, scabbed apparent scratch marks on the back of the left ear, petechiae on the chin and above the top lip, apparent bite marks on the tip of the tongue, a circular abrasion under the chin, a red circular bruise on the top of the center of the decedent's forehead into the hairline with a green color bruise to the right of that and a purple bruise under it, brown linear pattern discoloration on the skin from the left to right side of the front of the neck, a scabbed abrasion on the left side of the neck, a pink bruised area on the right temple area, a vertical linear scar on the right side of the face near the outer edge of the eye, an area of pink bruising and gray bruising on the right side of the head directly in front of the right ear, area of pink and gray bruising under the chin on the left side, two circular pink bruises on the top of the left forearm, a large area of pink bruising covering the right hip area from the inward towards the groin, a dark pink bruise under the penis on the right side of the scrotum, a large purple bruise covering the right side of the scrotum with swelling, dark pink bruising on the inside of the left groin extending downward under the scrotum, several small scabbed scratched on the left side of the base of the penis, three pattern linear gray bruises with a linear abrasion on the middle one down the outside of the left thigh, bruising on the outside of the leg just under the left knee, a faint gray bruise on the right thigh above the right knee, a small purple faded bruise on the shin above the ankle, a circular gray bruise on the top

of the left foot, small gray bruises on the top of the right foot near the base of the middle toe, there were several large faded bruises that appeared to be in various stages of healing on the decedent's lower back, a small circular gray bruise on the back of the decedent's left shoulder on the back, there were three circular abrasions on the middle of the decedent's back near the spine, a gray bruise on the decedent's back over the left side of the ribs, a small abrasion on the back of the right shoulder on the decedent's back, and a small abrasion on the outer right upper thigh. The decedent's rectum had an unusual appearance as the opening was linear and medical staff advised that it was not normal. It appeared that it may have possibly been altered in some way. I took digital photographs of the body and the injuries and those will be kept on file at the ECME office. While I was doing this Inv. Jones left the room and went to the family consultation room to speak to the decedent's parents. At the conclusion of taking my photographs I left the room and went to join Inv. Jones in the family consultation room.

I entered the room and Inv. Jones and Deputy Chance were speaking to a male later identified to me as Alan Shatto, the decedent's father. Mr. Shatto advised that he and his wife Laura Shatto had adopted the decedent and his younger brother Christopher from Russia through the Gladney Adoption agency out of Ft. Worth, Texas. He advised that they had gone to Russia to pick the boys up and had stayed there for two weeks. He stated that they arrived back in home with the boys on 11-3-12. He stated that the boys had been seen by an International Pediatrician he believed was named Dr. Beck in Denton at the Cook Children's Hospital as part of the adoption process. He advised that the decedent had begun to have behavior problems at home and that he was doing things such as throwing fits, pooping in the bathtub, hitting his head repeatedly against things, and throwing himself down on the floor. He advised that the decedent would not let Mrs. Shatto take him to the bathroom or bathe him and he would throw a fit and bang his head if she tried to so he would have to take the decedent to the bathroom. He advised that the decedent was not potty trained and was still in diapers. As a result of the decedent's behavior problems Mr. Shatto advised that the decedent was prescribed Risperidone 1mg/ml. He advised that they had it filled and that they had started the decedent on the medication on Tuesday (1-15-12) and he had taken it through Friday (1-18-12). He advised that on Friday (1-18-12) he was at work and the decedent had choked on a piece of carrot and his wife had to do the Heimlich maneuver on him. He said that due to this and the fact that they had researched the side effects of the medication and that one was difficulty swallowing they discontinued the medication. He advised that this date he had last seen the decedent at around noon. He said that the decedent had woken up that morning and was throwing a fit because Mrs. Shatto was trying to take him to the bathroom and so he took him. He advised that after the decedent went potty he asked him if he was going to behave and if he was going to get up or go back to bed. He said that the decedent went back to bed. Mr. Shatto left the house around noon and went to work. He advised that he received a call from Mrs. Shatto stating that the decedent was being taken to the hospital because he was unresponsive. When asked how they discipline the children Mr. Shatto advised that they did mostly with time outs and occasionally spanked them with their hands on the back of their legs. Inv. Jones spoke with Mr. Shatto regarding a search warrant and consent to search and then we left the room.

I led Inv. Jones and Deputy Chance back into the room where the decedent was located and we looked at the injuries on the decedent's body again. At this time I contacted Chief Inv. Shirley Standefer and briefed her on the case. She advised that she would contact me at the ED shortly. Inv. Jones advised that ECSO Investigators were at the decedent's residence at this time doing a search of the home. We then exited the room and went to the ED Lobby to make contact with Mrs. Shatto.

Mrs. Shatto was in the lobby with the decedent's younger brother. We led her into the MCH Security office to speak with her. Inv. Jones introduced us and advised her of the decedent's death. At this time Mrs. Shatto began hyperventilating and Inv. Jones advised her to breathe slowly and try to calm down so that she would not harm herself. Mrs. Shatto calmed down

slightly and we began to speak with her about the decedent's history. She advised that they adopted the decedent and his brother from Russia and that he had behavior problems. She stated that the decedent would bang his head on things and claw his self. She said that the decedent had choked on a piece of carrot and that he coughed it up when she did the Heimlich on him and that he had passed out and then began throwing up. She advised that she had gotten a bruise on the forearm from leaning him over the sink while he was throwing up. She said that he seemed alright afterwards. She said that he had bruises on the inside of his groin area and she thought that maybe he got those from falling out of the chair while choking. She said that he hadn't been himself lately. She then began to tell us that the decedent was sexually molested by the Host they stayed with while in Russia and that she had walked in on the woman holding the decedent's penis in her hand and masturbating him. She said ever since he grabs his penis and yanks on it and seems like he is trying to pull it off and leaves bruises and scratches on it. At this time Chief Inv. Standefer arrived in the room. Mrs. Shatto advised that she had the children in the back yard and that she had gone inside of the house to use the restroom and left the children outside. She advised that when she went back outside she found the decedent lying on his back on the ground and that he was not breathing. She then became very upset and said that she shook him very hard and was making statements that she had done this and it was her fault because she felt that she had shaken him too hard. She called 911 and EMS arrived and transported the decedent to the ED. Mrs. Shatto was brought to the ED later by Deputy Chance. Inv. Jones advised we were going to take her into the consultation room to be with her husband and we led her in there and left them in the room. We all then proceeded back to ED #14.

Upon arrival to the room we once again viewed the decedent's injuries and Inv. Jones requested that Dr. Diaz come into the room. Dr. Diaz advised that the decedent had several injuries but that he did not know the history. We asked Dr. Diaz if the decedent's rectum was normal and he advised that it was not normal. He then left the room. ECSO contacted CPS and they advised that they were on their way to the ED. Chief Inv. Standefer and I went back into the family consultation room to speak with the decedent's parents.

Mrs. Shatto advised us that the decedent had been seen by Dr. Bruce Eckel in Denton, Texas who was affiliated with Cook Children's Hospital. She advised that they had to see him because he was an international pediatrician that examined children adopted from other countries. She advised that the last time they saw Dr. Eckel was on 1-4-13. They stated that on the decedent's paperwork for adoption it was listed that the decedent had a heart murmur but that it had not been detected by Dr. Eckel and that he advised them that they may want to see a cardiology specialist later to rule this out. Mr. Shatto advised that it may have been on there because in order to adopt the children there had to be something medically wrong with the children such as the other child, Christopher, had a club foot. We asked Mrs. Shatto to tell us a timeline of the day's events leading up to finding the decedent unresponsive. She advised that the decedent had woke up at around 0800 – 0900 hrs and that he did not want to go to the potty with her. He began throwing a fit and Mr. Shatto took him to the bathroom. After the decedent went to the bathroom Mr. Shatto asked him if he was going to get back in bed or get up and he advised that the decedent did not really give him an answer and went and got back in bed. Mr. Shatto stated that he hung around the house until about 1200 – 1300 hrs and then went to work. Chief Inv. Standefer asked him if he normally went to work at that time and he stated that he usually went earlier but that the decedent was throwing a fit that morning and that he stayed home for a while because the decedent did not want to be around Mrs. Shatto and stayed in bed. He advised that the decedent had gotten used to him staying home during the Christmas holidays while he was off of work and that when he had to go back to work the decedent got upset and began banging his head on things and throwing fits. So this date he stayed home when he noticed that the decedent was upset. Mr. Shatto advised that they put Christopher down for a nap around 1100 hrs and that the decedent was still in his bed. Both boys shared a room. After Mr. Shatto went to work the decedent stayed in bed and Mrs. Shatto woke them up at 1500 hrs and took them to the potty. She advised that she tried to give the boys a snack and sippy cup and that

Max refused both which was unusual. She stated that they watched TV for a while and then around 1600 hrs she took both boys outside to play on the swing set. She advised that Christopher was playing normally but that Max was quiet and was standing around swaying from side to side but that it was not unusual for him to do that. They advised that he would sway from side to side, suck his thumb, and rock his head at night to self soothe. She stated that she had to go inside the house to use the restroom and when she went inside she thought that Max was getting on the slide. She advised that when she returned the decedent was lying on the ground on his back unresponsive near the swings. She advised that she went to the decedent and bent over and grabbed him with her hands on either side of his chest and called his name and began shaking him vigorously. She advised that the decedent had a history of holding his breath until he passed out and she thought he was doing that at this time. She advised that she was shaking him and that maybe she was shaking him too hard. She became upset and was making comments about that maybe she had done this by shaking him too hard. She advised that when the decedent wasn't responding she grabbed him by the neck with both hands and shook him hard. She advised that the decedent had bubbles with blood coming out of his mouth when she began shaking him and she thought that it was from him hurting his lip and making it bleed earlier this date. She then called 911 and EMS arrived. She advised that the decedent was not himself for the past couple of days. She said that on Friday 1-18-13 that she had cooked a meal that included cooked carrots. She advised that she had sat the boys down at the table to eat and that she had gone into the kitchen to wash dishes. She advised that Christopher screamed and that she went into the dining area and saw Max falling out of his chair onto the floor. She said that she went and got him up and noticed that he was making gurgling noises and figured out that he was choking. She began the infant Heimlich by laying him over her knee and hitting his back and it was not working so she picked him up and began doing the adult Heimlich on him from behind him thrusting her fists into his abdomen under his ribs until he coughed up a piece of carrot. She said that he then passed out and then began throwing up and she ran him into the bathroom and while she sat on the toilet seat she leaned him over the sink so that he could vomit into the sink. She advised that after this incident he seemed alright. Mr. Shatto was not present when this incident occurred as he was at work. They stated that they had looked up the side effects of the Risperidone and that one of them was difficulty swallowing and that they stopped giving him the medication because they believed that this was why he choked. They advised that he was acting tired and lethargic while he was on the medication. They stated that the decedent was displaying behaviors such as banging his head on the bathtub, throwing himself down, holding his breath, and clawing himself. They advised that they had to keep his nails cut short and put gloves on the decedent's hands at night so that he would not scratch himself. They stated that they had installed video cameras in the boy's bedroom so that they could monitor the decedent because he had gotten up out of bed and started hitting Christopher. Chief Inv. Standefer asked if they had recordings of the decedent in the bedroom and they said that the video camera did not record it was just so that they could see him on a monitor. They advised that they had installed motion detectors around the decedent's bed at night and that if he got out of bed it would record it but they did not clearly answer if they had recordings. They believed that the decedent may have some form of institutional form of autism from being in the orphanage in Russia for so long. Chief Inv. Standefer inquired about what they had to do as far as the adoption process. Mr. Shatto advised that they applied to adopt the children through the Gladney adoption agency out of Ft. Worth, TX. He advised that they made three trips to Russia in the process. He said that they went to Russia the first time to see the boys at the orphanage. He advised that approximately three months later they went back to Russia to attend a court hearing which granted them custody of the boys and they had to fill out paperwork for the USA and Russia to bring the boys to the USA. He said that after that they came back and waited for 30 days and then they were able to return to Russia to get the boys. He advised that when they went back to get the boys they had to remain in Russia for two weeks and stay with a host family before they were allowed to leave the country. They advised that they thought that the lady that was their host may have had dementia because she displayed some behavior similar to people that had dementia. Mrs. Shatto advised that the woman would do everything she could to keep them awake during the

night such as ring her own doorbell. Mr. Shatto advised that he did not hear her doing these things and Mrs. Shatto advised that he could sleep through a train. Mrs. Shatto advised that the woman sexually molested Max while they were there. She advised that she had seen Max from the other room with his pants down and she thought that maybe his pants had fallen down because he was so skinny. She said that the woman was trying to separate them from the children. She advised that she went into the room and observed the woman holding Max on her lap with his diaper and pants pulled down and that she was masturbating him. Mr. Shatto advised that they didn't know for a fact if the woman was sexually abusing him but Mrs. Shatto advised that she knew that she was for a fact because she saw her doing it. Mr. Shatto advised that what the deal was is that Max was bleeding from his penis and they thought that maybe he had a UTI and wanted to take him to the hospital in Moscow to be checked and the host didn't want them to and kept telling them that he didn't have a UTI. Mr. Shatto stated that they took him anyway and that he didn't have a UTI but that they didn't know why he was bleeding from the penis so they suspected that the decedent might have been sexually abused. Mrs. Shatto contended that she had witnessed it. Mr. Shatto advised that the host woman and Mrs. Shatto did not get along while they were there and that they butted heads frequently. During the course of our conversation CPS arrived in the room and they began speaking with the Shattos. We advised the parents that our office was going to order an autopsy in this case to be performed at the Tarrant County Medical Examiner's office in Ft. Worth, TX. We then excused ourselves from the room and went back to ED #14.

Chief Inv. Standefer and Inv. Jones left the scene at this time and I escorted the body of the decedent to the morgue at MCH with hospital security. Upon arrival to the morgue at 2005 hrs I secured the body of the decedent and the clothing into the cooler and left the morgue.

On 1-22-13 I contacted and spoke with Dr. Bruce Eckel. He advised that he had seen the decedent twice and advised me that the decedent's parents had advised him of the same behavior problems that they had described to us. He advised that the first time he saw the decedent the decedent had some bruising and a few scratches. He said that the second time that he saw the decedent which was about two weeks prior he looked much worse and had bruises and scratches all over him and had a hemorrhage in his left eye. He advised that he had prescribed the decedent the Risperidone because the behaviors that the parents were describing to explain the bruising and the injuries on the decedent was very severe and were consistent with a severe case of a child that was suffering from a major psychological problem. He advised that his records indicated that the decedent was born to a 23 year old Russian woman and that she had a history of drinking and that she was drinking while pregnant. He advised that the decedent lived with his birth family until he was 13 months old and then he was taken to the orphanage in Russia. He stated that he remained there until he was adopted and that there were allegations of possible abuse at the orphanage but that they were not proven. He advised that Christopher was the decedent's brother from the same mother but that he did not think that they knew each other because they were kept in different rooms at the orphanage and never interacted according to records that he had and the fact that Christopher was a year younger than Max. He said that he didn't know they family well and that he only had a medical history for two visits. I advised him that I would fax a medical records release to him so that they could send me their records and he advised that they would do so. I faxed the request to his office and received the records.

On 1-22-13 Chief Inv. Standefer and I met CPS at the morgue and we removed the body of the decedent from the morgue. We took digital photographs of the injuries described previously in this report and the changes that had occurred postmortem since I had placed the body into the morgue cooler on 1-21-13. There was a bag of clothing with the decedent's body that we had obtained from the ED. The bag contained a pair of blue jean overalls, a pair of white socks, and a pair of black and red shoes. Chief Inv. Standefer noted that none of these items or the clothing on the decedent or the decedent's back had any grass or dirt from laying on the ground


outside. We then placed the body back into the cooler and left the morgue. Those photos will be kept on file at the ECME office.

On 1-22-13 I spoke with a representative of the Gladney adoption agency and she advised that she would email me a copy of all the records that they had for the decedent. She advised that she had gotten consent from Mr. Shatto to release those records to us and that if there was a reference to Christopher in the decedent's records she was going to redact them in accordance to HIPPA. I advised her that this was fine.

Chief Inv. Standefer escorted Texas Overland to the morgue on 1-22-13 and they placed the decedent's body and the clothing in a white body bag and locked it with a lock numbered 0822222. The decedent was transported to the Tarrant County ME Office on this date for autopsy.

On 1-23-13 I contacted Mr. Shatto and he advised that they wished to use Nalley Pickle and Welch Funeral home in Midland, TX. I advised him that we would release the body of the decedent to them upon arrival.

End of Report.

A handwritten signature in black ink, appearing to read 'S. Woolf', is written over a horizontal line.

SONDRA WOOLF
INVESTIGATOR
TARRANT COUNTY MEDICAL EXAMINER

Evidence Chain of Custody
TARRANT COUNTY MEDICAL EXAMINER'S OFFICE
 200 Feliks Gwozdz Place
 Fort Worth, Texas 76104-4949

Case Number	1301059
Case Type	Non-Jurisdiction
Decedent's Name	Max Allan Shatto
Race	White
Age	3
Sex	M
Date of Death	1/21/2013 5:43:00 PM
Case Note	

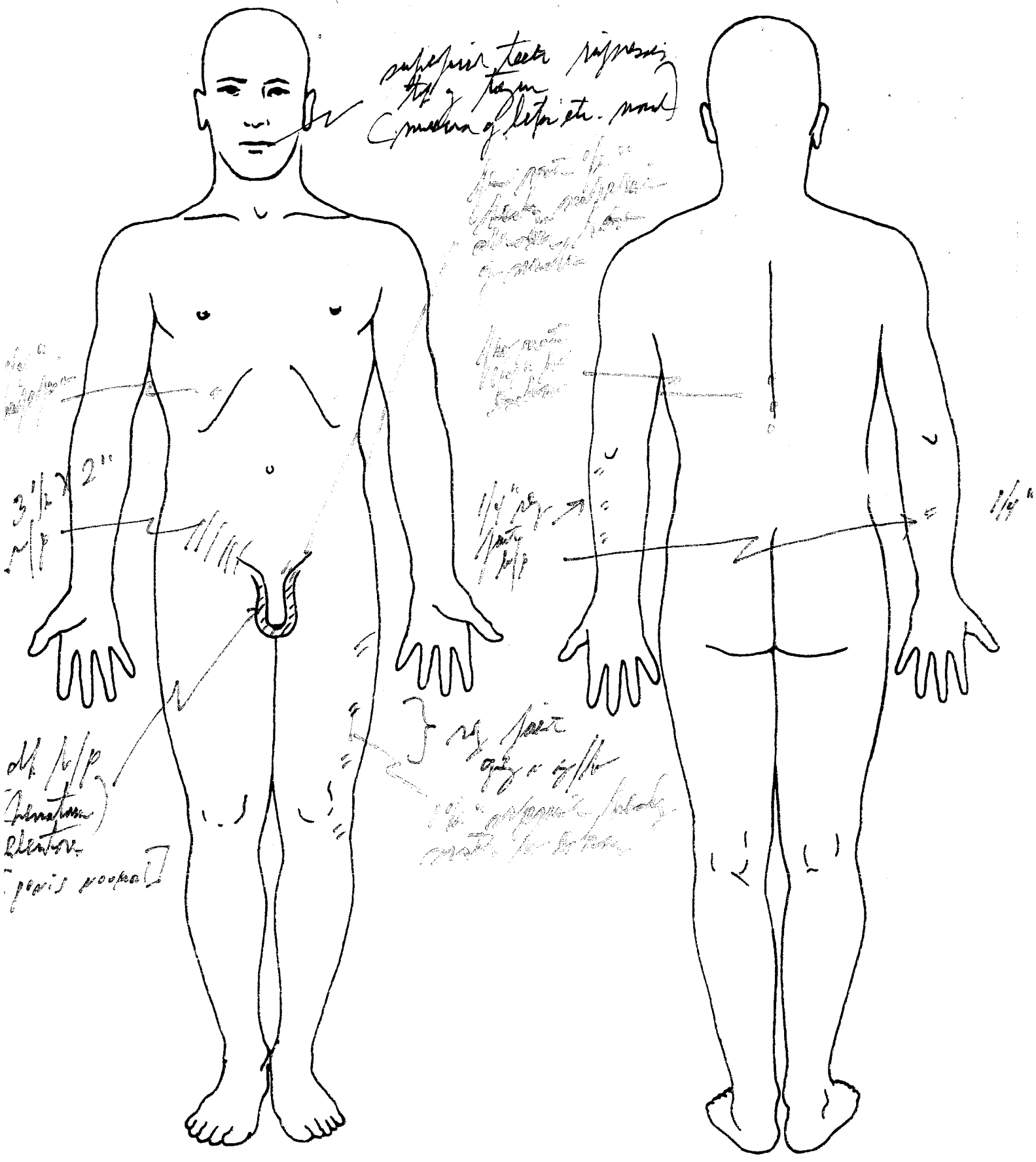
Exhibit Number	1	Description	Human Remains
Note:			
Date And Time	Relinquisher	Receiver	
1/22/2013 23:33:40	Robert Ruiz	William Shiro	
1/22/2013 23:33:40	William Shiro	Morgue Incoming Fridge	
1/23/2013 12:36	Morgue Incoming Fridge	LeRon Warren	
1/23/2013 12:36	LeRon Warren	Robert Ruiz	

Office of Chief Medical Examiner
Tarrant, Denton and Parker Counties, Texas

200 Feliks Gwozdz Place, Fort Worth, Texas 76104-4919 ♦ (817) 920-5700

Examiner: R.W. Cal

Autopsy No: 1301059

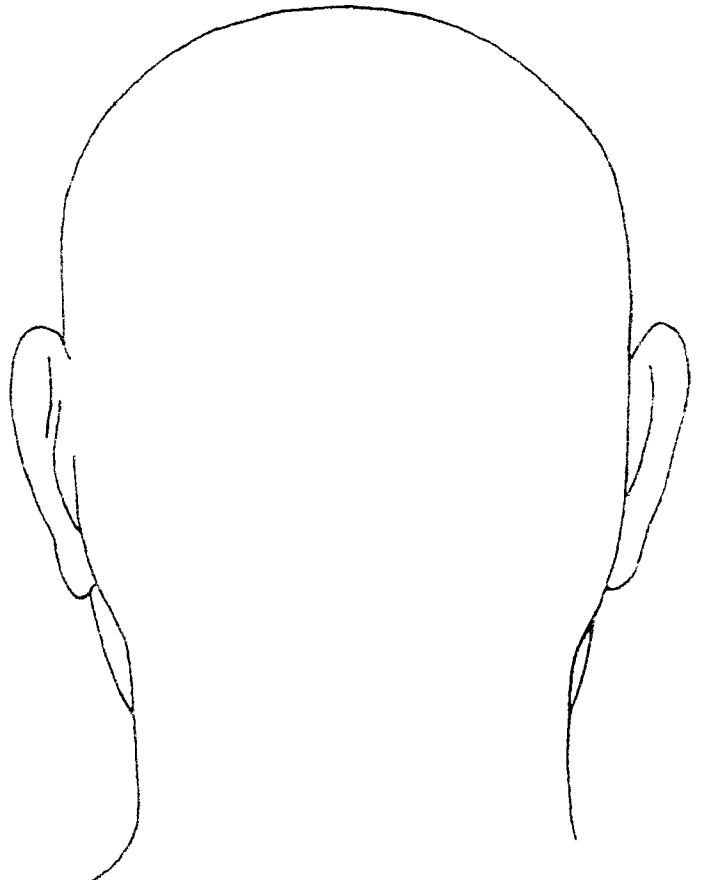
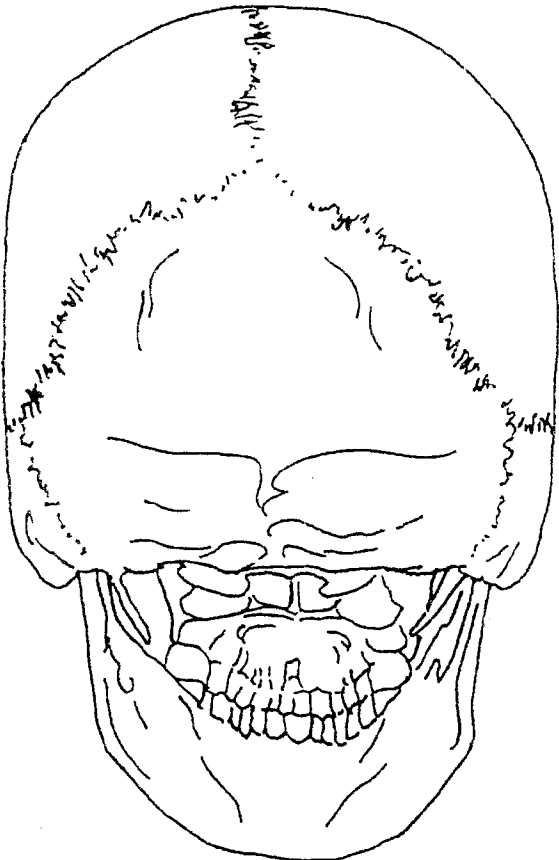
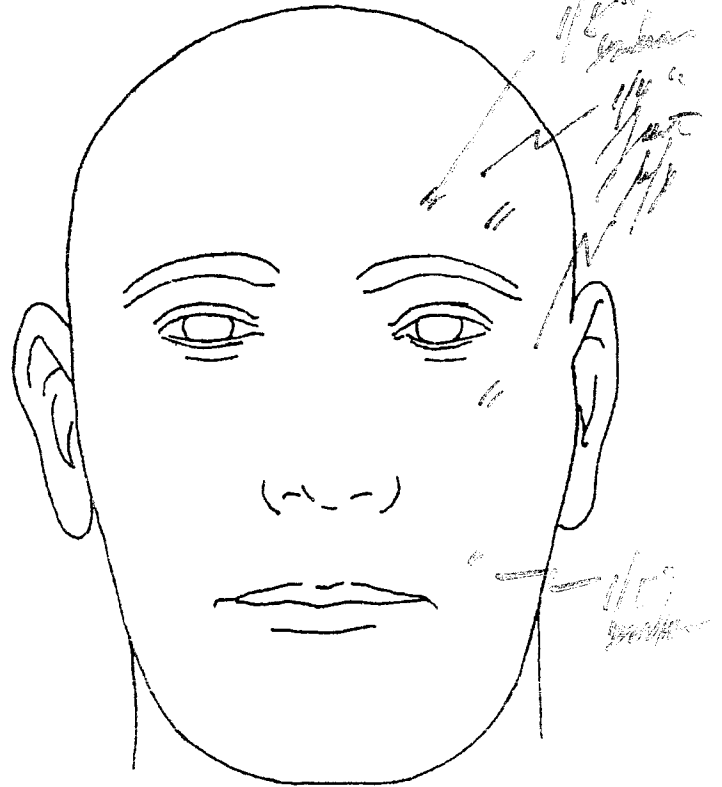
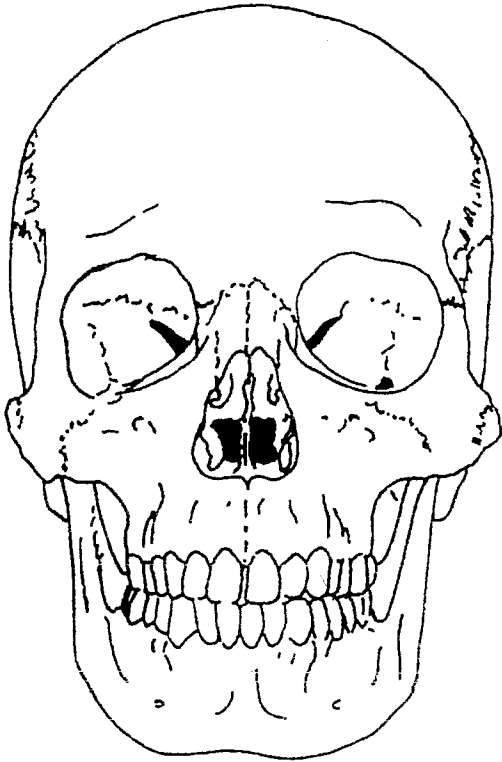


Office of Chief Medical Examiner Tarrant, Denton and Parker Counties, Texas

200 Feliks Gwozdz Place, Fort Worth, Texas 76104-4919 ♦ (817) 920-5700

Case No. 1301059

Examiner RW-CAL



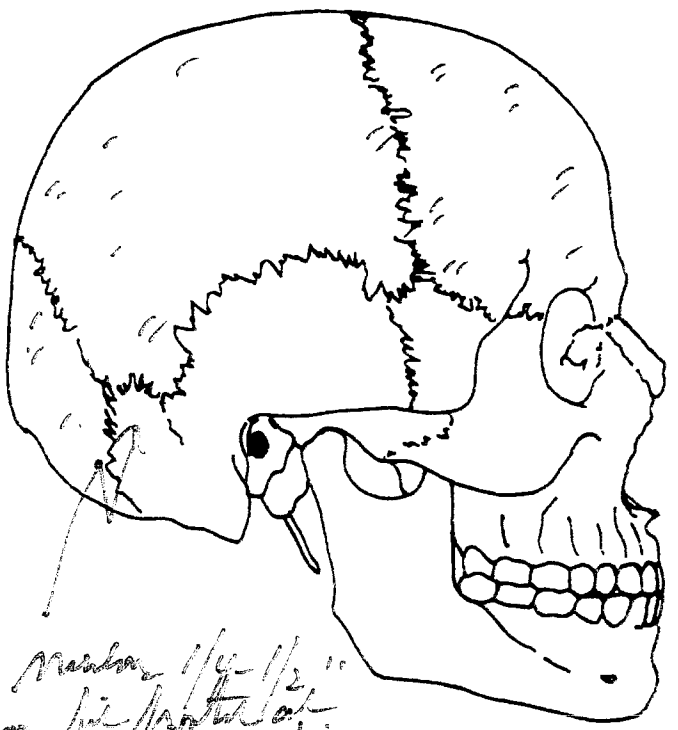
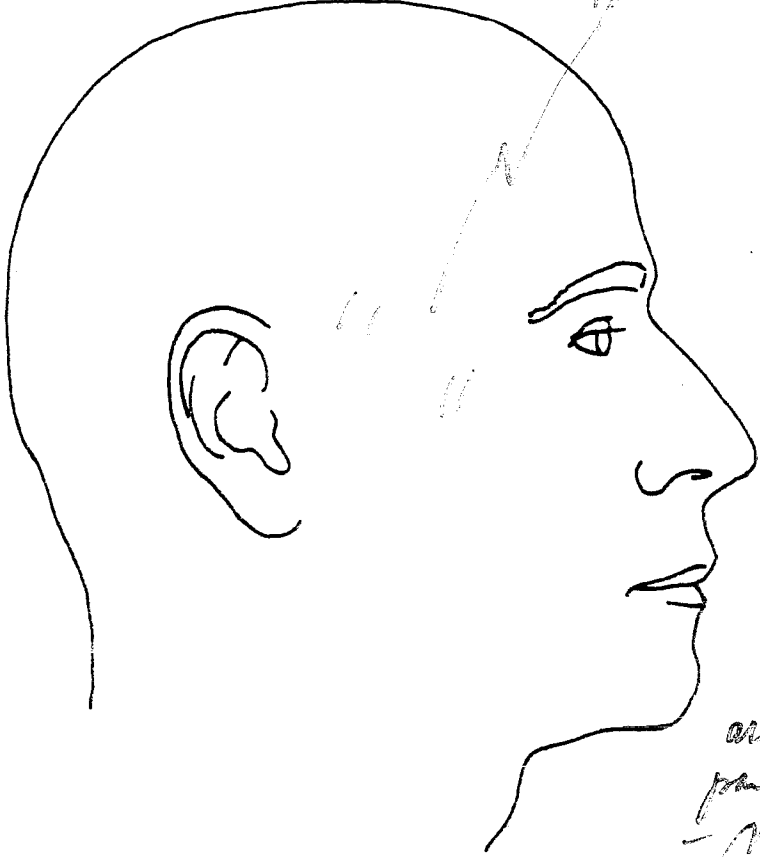
Office of Chief Medical Examiner Tarrant, Denton, Johnson and Parker Counties, Texas

200 Feliks Gwozdz Place, Fort Worth, Texas 76104-4919 ♦ (817) 920-5700

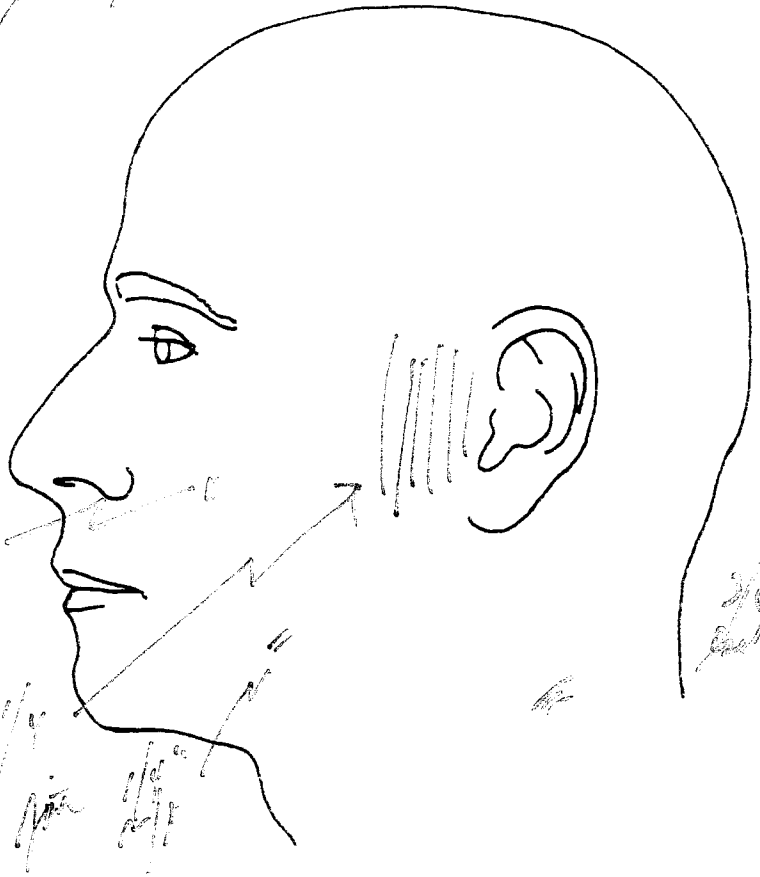
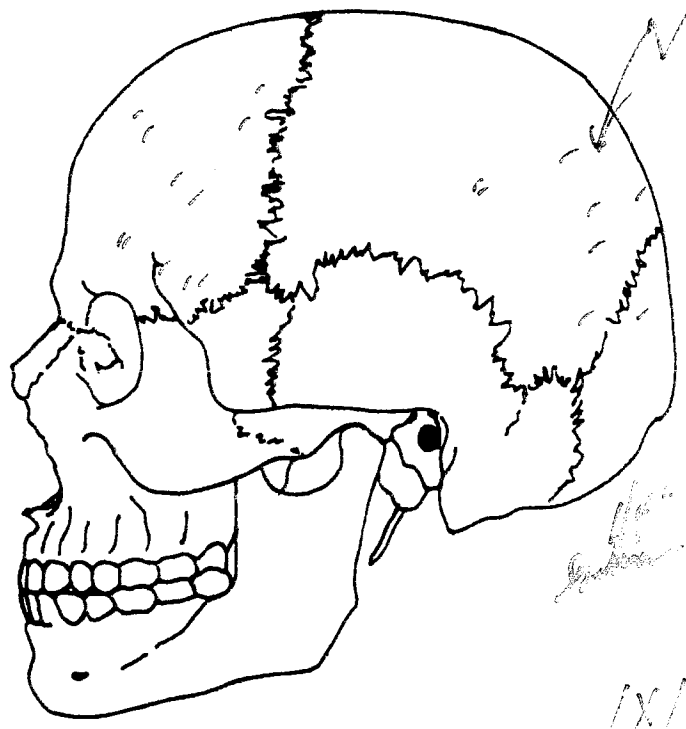
Case No: 1301059

Examiner: R.W. Cal

Handwritten notes:
1/20/11
1/20/11
1/20/11



Handwritten notes:
Marked 1/20/11
area for potential
post-occlusion - skin off
- 1/20/11



Handwritten notes:
1/20/11
1/20/11

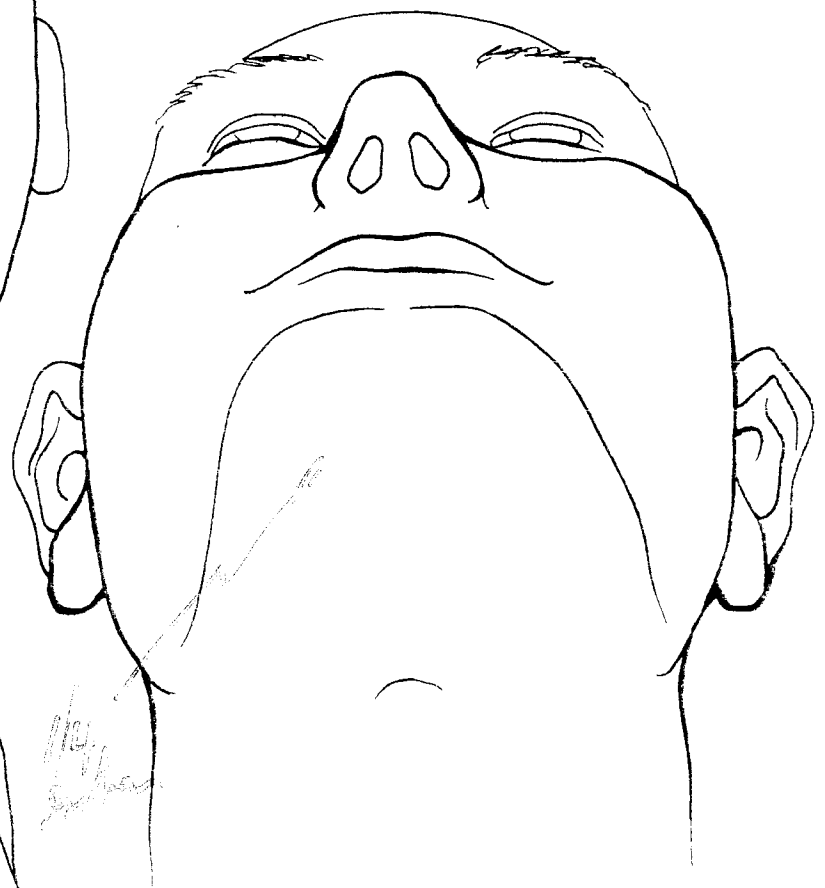

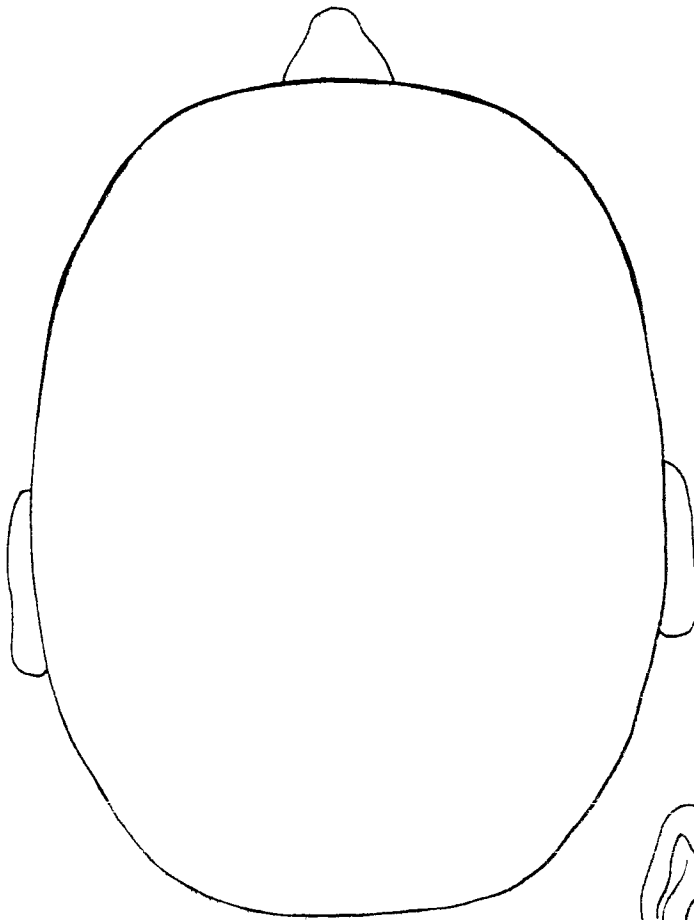
Handwritten signature:
R.W. Cal

Office of Chief Medical Examiner
Tarrant, Denton and Parker Counties, Texas

200 Feliks Gwozdz Place, Fort Worth, Texas 76104-4919 ♦ (817) 920-5700

Case No. 1301059

Examiner RW Cal



**TARRANT COUNTY MEDICAL EXAMINER'S DISTRICT
SERVING TARRANT, PARKER, & DENTON COUNTIES
Investigator's Report**

CASE #: 1301059 Ector TYPE: Non-Jurisdiction IDENTITY: Identified

NIZAM PEERWANI, M.D.
CHIEF MEDICAL EXAMINER

MICHAEL FLOYD
CHIEF FORENSIC DEATH INVESTIGATOR

DECEASED: Max Allan Shatto

ADDRESS: 16097 Waldrop, Gardendale, Texas 79758

AGE: 3

BIRTH DATE: 1/9/2010

MARITAL STATUS: Single

PHONE:

RACE OR COLOR: White

SEX: M

HEIGHT:

WEIGHT:

SSN:

MANNER OF DRESS:

OCCUPATION:

PLACE OF EMPLOYEMENT:

DATE OF DEATH: 1/21/2013

TIME OF DEATH: 17:43

PLACE OF DEATH DESCRIPTION: Emergency Room

ADDRESS OF DEATH: 500 W. 4th Street, Odessa, Texas 79761

HOSPITALIZED: Yes

ADMIT DATE: 1/21/2013

ADMIT TIME: 17:31

ENVIRONMENT CONDITION: HVAC controlled

CHARACTERISTIC OF PREMISES: Hospstital

DATE/TIME M.E. NOTIFIED: 1/22/2013 15:19

ARRIVED:

REPORTING PERSON: Sandra Woolf

REPORTING AGENCY: Ector County Medical

ADDRESS: 200-A West 3rd, Odessa, Texas 79761

PHONE: (432)617-8096

PRONOUNCED DEAD BY: Dr. Diaz

PRONOUNCING AGENCY: Medical Center Hospital

LAST TREATED BY: Dr. Bruce Eckel

DATE/TIME OF OCCURENCE: 1/21/2013 16:46

INJURY AT WORK: NO

PLACE OF OCCURENCE: Backyard of private residence

LOCATION: 16097 Waldrop, Gardendale, Texas 79758

TRAUMA RELATED: Yes

IDENTIFIED BY: James Greenwell

IDENTIFICATION TYPE: Visual

DATE/TIME OF IDENTIFICATION: 1/22/2013 -Time: 15:19

IDENTIFICATION STATUS: Positive ID

COMMENTS: FDI Woolf stated the decedent has been identified

ADDRESS:

PHONE:

NEXT OF KIN NOTIFICATION DATE/TIME: 1/21/2013 17:43

NOTIFIED BY: Dr. Diaz

NOTIFYING AGENCY: Medical Center Hospital

NEXT OF KIN NAME: Laura & Alan Shatto

RELATIONSHIP: Parents

COMMENTS:

ADDRESS: 16097 Waldrop, Gardendale, 79758 Texas

PHONE: (432)557-9258

BODY TO: TCMEO

CONVEYANCE:

FUNERAL HOME:

1/22/2013
Page 1



**TARRANT COUNTY MEDICAL EXAMINER'S DISTRICT
SERVING TARRANT, PARKER, & DENTON COUNTIES**

Investigator's Report

CASE #: 1301059

Ector

TYPE: Non-Jurisdiction

IDENTITY: Identified

NIZAM PEERWANI, M.D.
CHIEF MEDICAL EXAMINER


MICHAEL FLOYD
CHIEF FORENSIC DEATH INVESTIGATOR

NAME OF RELEASING AUTHORITY:

RELATIONSHIP:

DISPOSITION OF PROPERTY:

MEDICAL INVESTIGATOR:

James Greenwell 

TARRANT COUNTY MEDICAL EXAMINER'S DISTRICT
SERVING TARRANT, PARKER, & DENTON COUNTIES

INVESTIGATOR'S REPORT

NIZAM PEERWANI, M.D.
CHIEF MEDICAL EXAMINER
Case Number: 1301059

MICHAEL FLOYD
CHIEF FORENSIC DEATH INVESTIGATOR
Case Type: Non-Jurisdiction

DECEDENT'S NAME: Max Allan Shatto AGE: 3
ADDRESS: 16097 Waldrop, Gardendale, Texas 79758
BIRTH DATE: 1/9/2010 MARITAL STATUS: Single PHONE:

CASE NO. 1301059 Ector

The decedent, a 3-year-old White male recently adopted from Russia, was found unresponsive in the backyard of his private residence near a slide swing set, transported to the hospital by ambulance and where he was pronounced shortly after arrival.

Photographs: None
Total # of photos: 0

DESCRIPTION OF BODY:

The body will be viewed when it arrives at this office.

MEDICAL HISTORY:

According to Ector County Medical Investigator Sandra Woolf, the decedent has a medical history of self destructive behavior such as banging his head against a wall; (reported by parents). The PCP is Dr. Bruce Eckel, Pediatrician, who prescribed risperidone for the decedent on 01/04/2013. The parents did not start giving the decedent the prescribed medication until 01/15/2013, and stopped giving it to him on 01/18/2013 due to lethargy and a choking incident.

I have requested medical records via fax from Dr. Eckel and Cooks.

DETAILS OF INCIDENT:

Information about this death was obtained via a telephone interview with Ector County MI Sandra Woolf. She stated the decedent and another two year old were adopted from Russia by Laura and Alan Shatto, who picked the children up in Russia and returned to the United States on 11/03/2012. Sandra stated the decedent showed self destructive behavior as he was scratching himself with his fingernails and banging his head on solid objects. These events were reported to the PCP, Dr. Bruce Eckel, (940) 898-1477, out of Denton, TX. Dr. Eckel reported to have seeing the decedent on two occasions and observed bruises and abrasions on the decedent's body. The parents advised these marks were due to the decedent's self destructive behavior and the decedent was prescribed risperidone.

The parents did not begin to give the decedent the medication because they looked it up on the internet and worried about the potential side effects. They finally started giving the decedent the medication on 01/15/2013 and reported the decedent was acting very lethargic. The decedent's mother, Laura Shatto, reported the decedent choked on a cut carrot on 01/18/2013 so they stopped giving him the medication because she believed difficulty

with swallowing was a side effect.

On Monday, 01/21/2013 around 1600 hours, Laura took the decedent and his two year old sibling to the backyard to play. A short period of time later, she ran into the home to use the restroom leaving the children alone and unattended. When she returned, she found the decedent lying on the ground on his back near the swing portion of the slide swing set and he was unresponsive. She reportedly grabbed the decedent and began to shake him violently, then realized she was shaking him to hard. She then grabbed him by the neck and began shaking him, and then called 911.

Sandra said the 911 call was received at 1646 hours and paramedics arrived on scene at 1704 hours. They transported him to the hospital where he was pronounced shortly after arrival.

Sandra states there are cuts and bruises all over the body. She stated there appear to be a hicky on or near the decedent genitals as well as bruises. She stated the rectum appears to be deformed and possibly ripped. She said there are some sort of marks on the front and both sides of the neck and with a possible fingernail mark on the left side.

Sandra states the parents seem to pass off these injuries to the decedent's self destructive behavior. CPS has been notified and Detective David Jones of the Ector County SO is handling the investigation. She stated Detective Jones plans to be here for the autopsy. Sandra has been in contact with the Gladney adoption agency and has requested their records regarding the adoption. She is going to send copies of the hospital records from the ER visit as well as crime scene photos. She has also requested medical records via fax. She will forward a copy of the police report and her report once they become available.

ORGAN TISSUE DONOR:

There is no signed consent form to allow harvesting of organs or tissue.

CHILD FATALITY:

The decedent was born in Russia and the mother was reportedly an alcoholic. The adoptive parents reported the decedent was the victim of sexual abuse while in an orphanage in Russia; (unsubstantiated).

FOLLOW UP INVESTIGATIONS REQUIRED

No follow-up investigation is needed at this time.

COMMENTS:




James K Greenwell

*** TX REPORT ***

TRANSMISSION OK

TX/RX NO 1398
CONNECTION TEL 8pp4326173299pp8710123
CONNECTION ID
ST. TIME 01/24 08:10
USAGE T 00'27
PGS. SENT 2
RESULT OK



Tarrant County Medical Examiner
District Medical Examiner's Office
Serving Tarrant, Denton, Johnson and Parker Counties
200 Feliks Gwozdz Place*Fort Worth, Texas 76104-4919
(817) 920-5700*FAX (817)920-5713
Web site: tarrantcounty.com

FACSIMILE TRANSMITTAL SHEET

TO: ECM E
FAX NUMBER: 432 617 3299
DATE: 1-24-13

FROM: Dr. White
TOTAL NO. OF PAGES INCLUDING COVER: 2
OUR CASE NUMBER: 1301059

URGENT

FOR REVIEW

PLEASE REPLY

COMMENT:

TARRANT COUNTY MEDICAL EXAMINER
200 FELIKS GWOZDZ PLACE
FORT WORTH, TEXAS 76104-4919
(817)-920-5700; FAX (817)-920-5713

PRELIMINARY AUTOPSY RESULTS

23 January 2013

RE: Max Allan Shatto: M.E.# 1301059

Based on findings at this point, I suggest *Laceration of small bowel mesentery* due to *Blunt trauma to abdomen*, as the cause of death. I'll leave manner up to you pending investigation. On the whole, there appears to be a strong likelihood that this death is accidental, probably the consequence of a fall from playground equipment in his yard. Very sad case, nevertheless. Histology and toxicology have been submitted, and a complete report will be available shortly.



Lloyd White, M.D., Ph.D.
Deputy Medical Examiner

Please don't hesitate to call me should you have any questions.

OFFICE: 817-920-4700 x8393

HOME: 817-306-5323

CELL: 817-601-4775



Office of Chief Medical Examiner
Tarrant County Medical Examiner's District
Tarrant County, Texas
200 Feliks Gwozdz Place, Fort Worth, Texas 76104-4919
(817) 920-5700 FAX (817) 920-5713

AUTOPSY REPORT

Name: Max Allan Shatto
Approximate Age: 3 Years
Height: 37 Inches


CASE NO: 1301059
Sex: Male
Weight: 31 Pounds

I hereby certify that on the 23rd day of **January 2013**, beginning at 0945 hours, I, **Lloyd White, M.D., Ph.D.**, pursuant to autopsy request by Medical Examiner, of Ector County, Texas, performed a complete autopsy on the body of **Max Allan Shatto** at the Tarrant County Medical Examiner's District Morgue in Fort Worth, Texas and upon investigation of the essential facts concerning the circumstances of the death and history of the case as known to me, I am of the opinion that the findings, cause and manner of death are as follows:

FINDINGS:

- I) Pronounced dead at emergency room after being unresponsive on ground near playground equipment in back yard at home (by history)
- II) Medical history of severe behavioral disorder including self-destructive behavior and self-injury
- III) Minor healing contusions and abrasions of scalp, face, torso, and extremities
- IV) Hematoma of scrotum
- V) Recent contusions anterior to left external ear, and overlying right inguinal region
- VI) Laceration of small bowel mesentery, associated with intraperitoneal and retroperitoneal hemorrhage
- VII) Cerebral edema, mild, without herniation
- VIII) Pulmonary congestion and edema, mild
- IX) Blood toxicology negative
- X) No histopathology demonstrated on complete microscopic examination

CAUSE OF DEATH: LACERATION OF SMALL BOWEL MESENTERY DUE TO BLUNT TRAUMA TO ABDOMEN


Signature

**Lloyd White, M.D., Ph.D.
Deputy Medical Examiner**

A complete autopsy is carried out at the Tarrant County Medical Examiner's Morgue.

GROSS ANATOMIC DESCRIPTION

I. CLOTHING AND PERSONAL EFFECTS: The body is received in the autopsy room wrapped in a white cloth sheet, inside of a white vinyl remains removal pouch, and is dressed in blue denim overalls, a blue and black print shirt, white T-shirt, one white sock, two red and black shoes, and a disposable diaper soiled with a small amount of dark brown feces. Clothing has been partly removed by medical personnel, and accompanies the body in the bag.

II. THERAPEUTIC INTERVENTION: Evidence of medical treatment includes an orotracheal tube, and a left tibial needle.

III. EXTERNAL BODY DESCRIPTION:

The body is presumptively identified by ankle band and is that of a fair complexioned, conventionally white boy, 37 inches in stature, weighing 31 pounds (14.2 kg), and appearing the stated age of 3 years. Skin turgor suggests at least mild dehydration. Rigor is complete and there is pale blue-purple livor over the posterior body surface. Up to 1-1/2 inches in length scalp hair is straight and brown. Irides are brown, pupils are 4 mm in diameter and deciduous teeth are in good condition. External ears and ear canals are normal, nares are patent and the nasal septum is intact. There are no fractures, amputations, or congenital malformations of upper or lower extremities. External genitalia are those of a normally developed Tanner 1 boy, with both testes in the scrotum and the penis circumcised. Injury involving the scrotum is described below. A small amount of feces are evident on the perianal skin. The anus is grossly normal.

IV. EVIDENCE OF INJURY:

Apparent superficial teeth impressions, possibly representing postmortem artifact, are evident on the tip of the tongue. The oral mucosa is entirely normal. There is a 1/4-inch in diameter superficial abrasion on the lower right anterior chest at the edge of the rib cage, there is a roughly rectangular 3-1/2 x 2-inch red-purple contusion in the right inguinal region, there are a few no more than 1/2-inch healing superficial abrasions at the base of the scrotum on the left side, there are a few no more than 1/4-inch abrasions covered with eschar in the midline of the lower posterior chest, there are several no more than 1/4-inch in diameter very faint blue-purple contusions on the dorsal left forearm, with a single contusion of similar size and color on the dorsal right forearm, there are several very faint no more than 1-1/2-inch in dimension gray and yellow-brown healing contusions of the lateral left thigh and leg, and there is a 1-1/2-inch superficial healing scratch with eschar on the anterolateral left thigh just above the knee. The scrotum is edematous and dark blue-purple. The penis, however, is grossly normal.

Additional minor external injuries include a no more than 1/4-inch in diameter abrasion with eschar on the undersurface of the right side of the chin, two no more than 1/4-inch faint blue-purple contusions above the left eyebrow, a 1/8-inch abrasion covered with eschar above the left eyebrow, a 1/8-inch abrasion covered with eschar on the anterior left side of the face, a few very faint no more than 1/2-inch healing abrasions on the right face behind the eye, a 1/4-inch abrasion covered with eschar on the lateral left face just below the zygoma, a faint 1/4-inch red-purple contusion at the angle of the left side of the mandible, and an up to 3/8-inch diameter abrasion covered with eschar on the upper lateral left neck, below the ear. There is also an irregular up to 1 x 1-1/2-inch pale blue-purple contusion immediately anterior to the left external ear.

Reflection of the scalp reveals numerous approximately 1/4 to 1/2-inch in diameter faint blue-purple contusions in the skin extending across the bilateral frontal region and the bilateral parieto-occipital regions. These contusion hemorrhages do not extend into underlying galea or skeletal muscle. The skull, including calvarium and base of the skull, are subsequently demonstrated to be intact, and there are no intracranial injuries.

External examination of the torso reveals a measured 100 mL with an additional 50 mL estimated liquid blood in the inferior and anterior peritoneal space. There is also widespread soft tissue hemorrhage in the mesentery of the ileum on the right side. Major arterial branches in the abdomen, including the inferior mesenteric artery, are opened and demonstrated to be intact. A specific point of origin for the mesenteric hemorrhage, which is quite diffuse, is not grossly identified. This hemorrhage is associated with extensive retroperitoneal soft tissue hemorrhage throughout the right pelvis generally, extending across the midline in many areas, and also involving the right iliopsoas muscle, as well as extending into the right femoral region of the anterior thigh. Hemorrhage is evident in the deep skeletal muscle of the lower anterior abdomen, and also in the skin and subcutaneous fat tissue overlying the right anterior iliac crest, in the area of contusion previously described. Hemorrhage and congestion are noted as well in the serosa of the distal ileum and ascending colon, but the entire bowel is subsequently demonstrated to be intact and otherwise grossly normal. There are no visible or palpable fractures of the pelvis.

Dissection of the scrotum reveals an extensive bilateral recent hematoma. However, the testis and epididymis on both sides are demonstrated to be grossly normal.

V. INTERNAL EXAMINATION:

BODY WALL AND SEROUS CAVITIES:

The neck, chest and abdomen are opened by means of a standard Y-shaped incision. Viscera are examined *in situ* then removed for dissection according to the method of Virchow. Thoracic and abdominal walls are intact and normally developed, with a 1/8-inch anterior abdominal *panniculus adiposus*. Normally distributed subcutaneous fat tissue is moist and bright yellow. Pleural, pericardial, and peritoneal cavities are lined by smooth, blue-purple membranes without adhesions. Injuries have been previously described.

NECK ORGANS

Bones and cartilages of the larynx and cervical spine are intact, as is the hyoid bone, on palpation and direct gross visualization. On dissection of the soft tissues of the neck, no hemorrhage or other gross evidence of injury or natural disease are demonstrated.

CARDIOVASCULAR SYSTEM

The heart weighs 84.5 grams and the epicardium and endocardium are grossly normal, as are the coronary arteries and their major branches. Valve cusps are soft and pliable, with no anatomical stenosis or insufficiency. The cut surface of the myocardium is uniformly dark brown, without scars or other grossly discrete evidence of natural disease. The aorta and its major branches are grossly normal, and the great veins are normal as well.

RESPIRATORY TRACT

The left lung weighs 137.0 grams and the right 120.5 grams. Airways are patent, containing no foreign objects or material, and the mucosa is covered by abundant, somewhat frothy, pale gray mucus. Both lungs are focally firm, non-crepitant, and somewhat boggy in consistency, with smooth, shiny dark blue-purple external surfaces, and moist dark red-purple cut surfaces which ooze frothy, thin dark gray or red-purple fluid on sectioning. However, portions of both lungs are soft, pink and well-aerated.

GASTROINTESTINAL TRACT

The gastric lumen is empty. The mucosa and wall of the esophagus and stomach are normal in appearance. Injury has been previously described. The vermiform appendix is grossly normal.

MAJOR DIGESTIVE ORGANS

The pancreas is soft and uniformly pale brown, dissection revealing no masses, hemorrhage, or other grossly discrete abnormalities.

The liver weighs 406.5 grams, with a blue-purple capsule, and a uniform dark brown cut surface. Wide dissection reveals no cysts, masses, or other grossly discrete lesions of natural disease, and the parenchyma is normal in consistency. The gallbladder contains an estimated 2 mL of dark yellow-green bile without stones, and the extrahepatic biliary tract is patent and grossly normal.

LYMPHORETICULAR SYSTEM

The spleen weighs 44.0 grams, with a dark blue-purple capsule and a firm, uniformly dark red-purple cut surface without scars, infarcts, or other grossly discrete abnormalities of natural disease. There is no lymphadenopathy, and spinal bone marrow is normal in appearance.

The thymus weighs 15.5 grams. External and cut surfaces are uniformly pale gray-brown. The parenchyma is normal in constancy and dissection reveals no masses, cysts, or other gross pathological changes.

ENDOCRINE ORGANS

The pituitary, thyroid, parathyroids, and suprarenals are grossly normal.

URINARY TRACT

The left kidney weighs 49.5 grams and the right 42.0 grams. Capsules strip easily to reveal smooth, brown external surfaces. Cut surface architecture is normal, there being no cysts, masses, or other grossly discrete pathologic lesions. Pelves and ureters are patent and normal in appearance. The urinary bladder and the mucosa and wall are grossly normal.

REPRODUCTIVE ORGANS

Injury involving soft tissues of the scrotum has been previously described.

CRANIUM AND CENTRAL NERVOUS SYSTEM

A craniotomy and removal of the brain are carried out through a coronal mastoid-to-mastoid incision of the scalp, reflection of which reveals minor contusions which are described above. The calvarium is intact and normal in configuration. The dura is normal in appearance and the leptomeninges are transparent and grossly normal. Cerebrospinal fluid is unremarkable. There are no abnormalities of the vessels at the base of the brain. The brain weighs 1058.0 grams, with mild symmetrical flattening of gyri over the convexities of the cerebral hemispheres. The basilar cistern is widely patent and no herniation is present. Multiple transverse sections of brainstem and cerebellum, together with coronal sections of the cerebral hemispheres, reveal no cysts, masses, hemorrhage, or other gross evidence of injury or natural disease. On stripping of the dura, the base of the skull is intact and normal in configuration.

The spinal cord is not examined.

SPECIMENS AND EVIDENCE COLLECTED

1. 10 mL of femoral blood, 20 mL of aortic blood, 3 mL of vitreous humor
2. Representative tissue samples retained in formalin
3. 15 tissue cassettes for microscopic examination
4. One blood card
5. One metabolic screen card
6. Representative photographs
7. Three x-rays (no obvious skeletal trauma)

MICROSCOPY

HEART: The epicardium and endocardium are normal, and the myocardium is composed of an orderly arrangement of uniform cardiac muscle fibers without inflammation or other histopathologic changes.

PANCREAS: Acini and islets are generally well-preserved, without inflammation or other histopathology.

GASTROINTESTINAL TRACT: Sections of stomach, small bowel, and colon reveal no histopathologic changes.

RESPIRATORY TRACT: In sections of lung, there is minimal focal atelectasis, typical of resuscitation artifact. Alveoli generally are well-aerated, however. Bronchi, bronchioles, and arterioles are normal, and there is no pneumonia.

THYMUS: The thymus is histologically normal.

THYROID: Thyroid architecture is normal for a child of this age.

ADRENAL: Sections of both adrenals reveal no histopathology.

KIDNEY: Sections of both kidneys reveal normal histology.

LIVER: Lobular architecture is intact, and no fibrosis, necrosis, inflammation or other histopathologic changes are present.

SPLEEN: Follicular and sinusoidal architecture is well-preserved. A few small germinal centers are scattered throughout, and the cell population is normal.

MESENTERY: A section of small bowel mesentery reveals diffuse acute hemorrhage without cellular reaction.

EDC: 03/22/13

Dictated: 01/29/13

Transcribed: 01/29/13

Completed: 02/13/13

LW:cal

Toxicology M.E. Request Form

Name: Max Allan Shatto
M.E. Case Number: 1301059
Date of Death/Found: 1/21/2013 5:43:00 PM
Prosecutor: Lloyd White, M.D.
Hospital Name:



Tox Number: 1300247
Date of Inquest: 1/23/2013 12:12:14 PM
Hospitalization: Yes
Medications: No
Priority: 2

Test Requested:

- (x) ABN Screen
- (x) Amphetamine and Benzodiazepines Screen
- (x) Ethanol
- (x) Opiates, THC, Cocaine Screen

Remarks:

Specimens Submitted

Description	Amount	ItemNumber	
Blood, Femoral	10.00 Milliliters	130123065	✓  1 3 0 1 2 3 0 6 5
Blood, Aorta	20.00 Milliliters	130123066	✓  1 3 0 1 2 3 0 6 6

Cause of Death: LACERATION OF SMALL BOWEL MESENTERY
Method of Death: NON-JURISDICTIONAL

Released By: *Ethan Gutierrez*

Date: 1-24-13 @ 0820

Received By: *Devin Lindsey*

Date: 1-24-13 @ 0825

Toxicology Test Results

Office of Chief Medical Examiner
Toxicology Laboratory Service
200 Feliks Gwozdz Place
Fort Worth, Texas 76104
Name: **Max Allan Shatto**
Case Number: **1301059**
Toxicology Work Number: **1300247**

Nizam Peerwani, M.D., DABFP
Chief Medical Examiner
Robert Johnson, PH.D., DABFT
Chief Toxicologist
Priority: **0**
Service Request Number: **002**

Specimen	Drug	Result	Drug Amount	Performed By
AORTA BLOOD	ETHANOL	NEGATIVE		J. HO
AORTA BLOOD	AMPHETAMINE ELISA	NEGATIVE		B. LANDRY
AORTA BLOOD	METHAMPHETAMINE ELISA	NEGATIVE		B. LANDRY
AORTA BLOOD	THC ELISA	NEGATIVE		B. LANDRY
AORTA BLOOD	OPIATES ELISA	NEGATIVE		B. LANDRY
AORTA BLOOD	COCAINE ELISA	NEGATIVE		B. LANDRY
AORTA BLOOD	BENZODIAZEPINES ELISA	NEGATIVE		B. LANDRY
AORTA BLOOD	OXYCODONE ELISA	NEGATIVE		B. LANDRY
AORTA BLOOD	ACID	NEGATIVE		T. FLOWERS
AORTA BLOOD	BASE	NEGATIVE		T. FLOWERS

Report Prepared By: *B. Landry*

Approved By: *[Signature]*

Approved Date: 2/1/13

Octor County
Dr. Sandra Woolley

RW-CAL